

Preventive Effect of Vitamin B6 on Developmental Toxicity of Carbamazepine in Mice

¹Mohammad Afshar, ^{*2}Seyed Adel Moallem, ³Javad Baharara, ³Toktam Takjo, ⁴Mohammad Jafar Golalipour

Abstract

Objective(s)

Carbamazepine (CBZ) is an antiepileptic drug that is used widely for the treatment of epileptic seizures. Neural tube defects (NTDs), growth retardation, and nail hypoplasia are the most common features of teratogenic effects of this drug. The purpose of this study was to examine the effect of vitamin B6 on the developmental toxicity of CBZ on mice.

Materials and Methods

Sixty BALB/c pregnant mice were divided into four experimental and two control groups. Two experimental groups received daily intraperitoneal injection (IP) of 30 mg/kg (I) or 60 mg/kg (II) of CBZ on gestational days (GD) 6 to 15. Two other experimental groups received daily IP injection of 30 mg/kg (III) or 60 mg/kg (IV) of CBZ with 10 mg/kg/day vitamin B6 by gavage 10 days prior to gestation and on GD 6 to 15. Two control groups received normal saline or Tween 20. Dams underwent Cesarean section on GD 18 and embryos were harvested. External/macrosopic observation of fetuses was done by stereomicroscope and external examination for malformations was recorded. Data analyzed by ANOVA and X² test using SPSS software.

Results

The mean weight and crown-rump of the fetuses in both CBZ-treated experimental groups were significantly reduced compared with those of the control groups. Various malformations were detected such as brachygnathia, eye malformations, NTDs, vertebral deformity, brachydactyly and growth retardation. Vitamin B6 treatment significantly reduced various CBZ-induced malformations.

Conclusion

This study showed that vitamin B6 has a preventive effect on the developmental toxicity of CBZ in mice that can be pursued further for clinical research.

Keywords: Carbamazepine, Congenital Abnormalities, Pyridoxine, Teratology, Mice

1- Department of Anatomy, Birjand University of Medical Sciences, Birjand, Iran

2- Pharmaceutical Sciences Research Center, Medical Toxicology Research Center, Department of Pharmacodynamics and Toxicology, Mashhad University of Medical Sciences, Mashhad, Iran

*Corresponding author: Tel: +98-511-8823255; Fax: +98-511-8823251; email: moallem@mums.ac.ir

3- Department of Biology, Azad Islamic University of Mashhad, Mashhad, Iran

4- Gorgan Congenital Malformations Center, Golestan University of Medical Sciences, Gorgan, Iran

Introduction

Carbamazepine (CBZ) is one of the most widely used antiepileptic drugs in the clinic. It is highly effective for partial onset seizures, including cryptogenic and symptomatic partial seizures. It has also demonstrated good efficiency in the treatment of generalized tonic-clonic seizures, trigeminal neuralgia, and mood disorders (1, 2). Chemically, CBZ is a neutral, lipid soluble compound that can easily pass the blood brain barrier and other membranes in the body. This drug is highly effective, well tolerated and compared to other antiepileptic drugs considered relatively safe during pregnancy and therefore is used by pregnant women (3-5).

Antiepileptic treatment during pregnancy is associated with two to three fold increase in the rate of major congenital anomalies (5-7), mainly as neural tube defects (NTDs), congenital heart malformations (7), cleft lip and cleft palate, anomalies of the urinary tract (5, 8), skeletal anomalies, growth retardation, and developmental delays (9). Recently, some studies showed eye malformation due to CBZ (10, 11).

The role of vitamin B6 as antioxidant and its ability to lower damage due to oxidative stress and protecting against neurodegenerative disorders has been suggested (12). Some studies have shown that using antiepileptic drugs including CBZ in seizure patients reduces serum level of vitamin B6 which leads to hyperhomocysteinemia (13, 14). One of the teratogenic mechanisms of homocysteine is production of free radical that leads to oxidative stress (15). However, there are few reports on the effect of vitamin B6 in protecting against congenital anomalies. This study has been carried out to determine the effect of vitamin B6 on the developmental toxicity of CBZ during organogenesis in BALB/c mice.

Materials and Methods

Animals and Treatment

Virgin female BALB/c mice, weighting 28-30 gram (8-9 weeks old) were used in this study. The animals were maintained in a climate-controlled room under a 12 hr alternating light/dark cycle (9.00- 21.00 hr light), 20.1 to

21.2 °C temperature and 50 to 55.5 % relative humidity. Dry food pellets and water were provided *ad libitum*. After two weeks of acclimation to the diet and the environment, three females were caged with a male of the same strain overnight. The presence of vaginal plug in the following morning confirmed that mating had taken place and was designated as gestation day (GD) 0. Maternal weights were measured throughout the experiment. Sixty pregnant mice were randomly divided into 4 experimental groups receiving 30 mg/kg/day CBZ on GD 6 to 15 in experimental group I, 60 mg/kg/day CBZ on GD 6 to 15 in experimental group II, 30 mg/kg/day CBZ with 10 mg/kg/day vitamin B6 10 days prior to gestation and on GD 6 to 15 in experimental group III, 60 mg/kg/day CBZ with 10 mg/kg/day vitamin B6 10 days prior to gestation and on GD 6 to 15 in experimental group IV and two control groups that received normal saline (routine control) or Tween-20 (vehicle control). All CBZ (and control compounds) and vitamin B6 were administered by intraperitoneal injection and gavage, respectively. Ten mice were used in each group. CBZ powder was obtained from Mehr Darou Pharmaceutical Company in Tehran, Iran and was dissolved in 0.1 % Tween-20 (Merck, Germany) in normal saline. Vitamine B6 ampoules were made by Daroupakhsh (Tehran, Iran).

This study has been approved by the Animal Care Committees of Mashhad University of Medical Sciences and Birjand University of Medical Sciences, Iran.

Fetal assessment

On GD 18, pregnant mice were sacrificed under ether anesthesia and the uterus was opened and the umbilical cord cut close to the fetus; each fetus and placenta were then weighed (Sartorius PT210, Switzerland). Fetuses were assessed as either alive or dead and any resorption noted; live fetuses were then euthanized by hypothermia. Crown-rump of each fetus was measured and examined externally for malformations or deviations from normal growth. Fetuses were observed by a stereo research microscope (Olympus SZX, Japan).

Statistics

For numbers of implantations, fetal body weight, and crown-rump length, the unit of analysis was litters and data are reported as mean \pm SD. Tukey test was done after ANOVA between control groups and each treated group. In regards to the frequency of absorbed fetuses, external malformation differences between the control groups and each treated group were tested with the χ^2 test when the frequency of each category was 5 or more, and with Fisher's direct probability test for other cases. The unit of frequency analysis was fetuses. All analyses were carried out with SPSS software (Ver 11.5). Differences were considered significant at $P < 0.05$.

Results**Maternal observations, body weight and food consumption**

All females survived to the scheduled study termination on GD 18. There were no postmortem findings in mothers judged as treatment-related. There were no significant differences in absolute maternal body weight in any of the treatment groups at any time during the study. No significant changes in maternal body weight gain were observed in any treatment group during the overall gestation period (GD 0-GD 18). There were no significant changes in mean food consumption between the experimental groups and the control groups (above data not shown).

Reproductive parameters

Findings upon Cesarean section on GD 18 are shown in Table 1. CBZ exposure resulted in fetal resorptions in both experimental groups and it was statistically significant in the treated groups I (6.77%) and II (8.87%) as compared with the normal saline and Tween control groups. On the other hand, fetal resorptions in experimental groups III (9.89%) and IV (6.93%) were not significant as compared with the experimental groups I and II.

The mean fetal body weight of experimental group I (0.68 ± 0.21 g) and II (0.72 ± 0.18 g) were significantly reduced compared to the control groups (Tween and normal saline groups, 1.14 ± 0.19 g and 1.22 ± 0.18 g, respectively). The mean fetal body weight of

experimental group III (0.92 ± 0.44 g) was significantly increased as compared with experimental group I. However, the mean fetal body weight of experimental group IV (0.69 ± 0.93 g) was not significantly different from experimental group II.

Crown-rump lengths of live fetuses were also reduced significantly in both experimental groups I and II as compared with both control groups (Table 1). The mean crown-rump lengths of experimental group III was significantly increased as compared with experimental group I. However, the mean crown-rump length of experimental group IV was not significantly different from experimental group II (Table 1).

The details of the gross malformations in mouse fetuses due to CBZ administration are shown in Table 2. Brachygnathia (mandibular hypoplasia), open eyelid, vertebral deformity and brachydactyly were often found in the malformed fetuses. A few fetuses had severe malformations.

Fetuses with ocular anomalies

Premature opening of one or both eyelids with mild to severe exophthalmos occurred in 7.27% and 6.19 % of fetuses in experimental groups I and II, respectively. Lesions were often bilateral and approximately symmetrical. The percent of premature opening of one or both eyelids in experimental group III (1.21%) was significantly decreased as compared with experimental group I ($P < 0.05$). Furthermore, the percentage of premature opening of one or both eyelids in experimental group IV (1.06%) was significantly decreased as compared with experimental group II (Table 2).

Fetuses with limb anomalies

Limb anomalies occurred in 13.63% and 12.38% of fetuses in experimental groups I and II, respectively (Figure 1). The most frequent limb anomaly which was seen in these groups was brachydactyly. The percentage of limb anomalies in experimental group III was significantly decreased as compared with experimental group I ($P < 0.05$). Furthermore, the percentage of limb anomalies in experimental group IV was significantly decreased as compared with experimental group II (Table 2).

Fetuses with facial anomalies

Brachygnathia occurred in 10.9% and 10.61% of fetuses in experimental groups I and II, respectively (Figure 2). This malformation was associated with open mouth in many of the malformed fetuses. The percentage of brachygnathia in experimental group III and IV was significantly decreased as compared with experimental group I and II ($P < 0.05$) (Table 2).

Fetuses with vertebral anomalies

Vertebral anomalies (more frequently in the form of scoliosis) occurred in 6.36% and 7.96% of fetuses in experimental groups I and II, respectively. The percentage of vertebral anomalies in experimental group III and IV was significantly decreased as compared with experimental group I and II ($P < 0.05$) (Table 2).

Fetuses with neural tube defects

NTDs occurred only in 2.65% of fetuses in experimental groups II in the form of exencephaly (Figure 3). NTDs were not observed in other experimental and control groups.

Fetuses with severe malformations

Major malformations occurred in 4.54 % and 6.19 % of fetuses in experimental groups I and II, respectively (Figure 4). The percentage of major malformations in experimental group III (1.21%) was not significantly decreased as compared with experimental group I. Moreover, the percentage of major malformations in experimental group IV was decreased as compared with experimental group II (3.19%). However, this was not significant (Table 2).

Table 1. Cesarean section parameters on GD 18 of BALB/c mice treated with carbamazepine (CBZ) and (CBZ)+Vitamin (Vit) B6.

Parameters	Control groups		Experimental groups			
	Normal saline	Tween 20	30 mg/kg CBZ	60 mg/kg CBZ	30 mg/kg CBZ+ Vit B6	60mg/kg CBZ+Vit B6
Pregnant mice (No)	10	10	10	10	10	10
Live fetuses No (%)	121 (100)	115 (100)	110 (93.22)	113 (91.13)	82 (91.1)	96 (93.06)
Resorptions No (%)	0 (0)	0 (0)	8* (6.77)	11* (8.87)	9† (9.89)	7† (7.09)
Fetal body weight (gr) Mean±SD	1.19±0.15	1.12±0.19	0.68±0.21*	0.71±0.18*	0.92±0.44††	0.69±0.93†
Crown-rump length (mm) Mean±SD	23.63±1.99	22.97±1/78	17.76±2.14*	18.52±1.85*	18.21±3.41†	17.91±1.19†

* $P < 0.05$, ** $P < 0.01$ between control and experimental groups.

† $P < 0.05$ between experimental groups with and without vitamin B6.

Table 2. External malformations in BALB/c mice treated with carbamazepine (CBZ) and (CBZ)+Vitamin (Vit) B6.

Parameters	Control groups		Experimental groups			
	Normal saline	Tween 20	30 mg/kg	60 mg/kg	30 mg/kg CBZ+Vit B6	60 mg/kg CBZ+Vit B6
Pregnant mice (No)	10	10	10	10	10	10
Fetus examined (No)	121	115	110	113	82	96
Open eyes No (%)	0 (0)	0 (0)	8* (7.27)	7* (6.19)	1†† (1.21)	1†† (1.06)
Little mandible No (%)	0 (0)	0 (0)	12* (10.90)	12* (10.61)	2†† (2.43)	0 ††† (0)
Vertebral deformity No (%)	0 (0)	0 (0)	7* (6.36)	12* (7.96)	0††† (0)	0††† (0)
Short fingers No (%)	0 (0)	0 (0)	15* (13.63)	14* (12.38)	1††† (1.21)	2††† (2.12)
Neural tube defects No (%)	0 (0)	0 (0)	0 (0)	3* (2.65)	0 (0)	0†† (0)
Severe malformations No (%)	0 (0)	0 (0)	5* (4.54)	7* (6.19)	1†† (1.21)	3†† (3.19)

* $P < 0.05$, ** $P < 0.01$ between control and experimental groups.

† $P < 0.05$, †† $P < 0.01$, ††† $P < 0.01$ between experimental groups with and without vitamin B6.

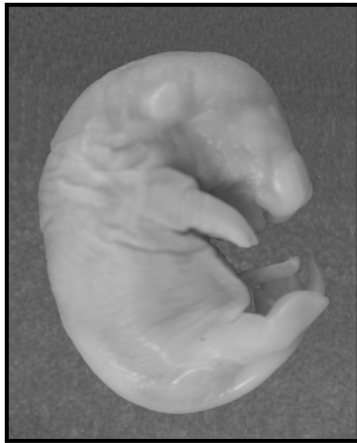


Figure 1. Limb malformation due to treatment with 30 mg/kg carbamazepine.

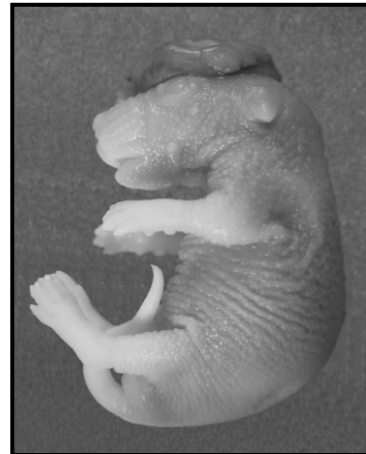

Figure 3. Exencephaly due to treatment with 60 mg/kg carbamazepine.

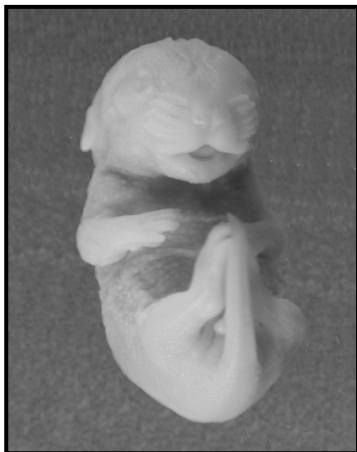


Figure 2. Brachygnathia due to treatment with 30 mg/kg carbamazepine.

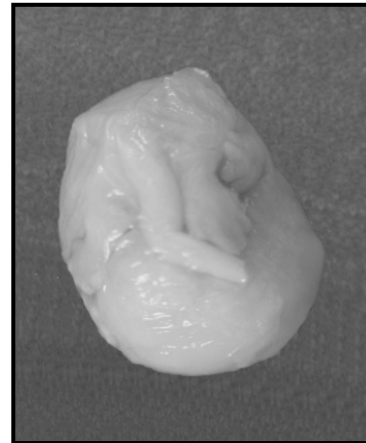


Figure 4. Major malformation due to treatment with 60 mg/kg carbamazepine.

Discussion

In the present study, CBZ showed negative effects on growth indexes of fetuses. Reductions of fetal body weight and crown rump length were seen in both CBZ treated groups as compared with control groups. Moreover, fetal resorptions were observed in both CBZ treated groups. These findings are similar to other studies (5, 16-19).

There is some considerable controversy concerning the preventative effect of vitamin B6 on growth indexes of fetuses. In one study, it has been shown that there is no relation between vitamin B6 and growth indexes (20). On the other hand, Schuster *et al* showed that mean of weights of neonates of mothers with vitamin B6 deficiency during pregnancy were lower than neonates of mothers with no vitamin B6 deficiency (21). Furthermore, it

has been reported that no reduction of fetal body weight is noticed in mothers who consumed folic acid and vitamin B6 during pregnancy with history of low fetal body weight in previous pregnancies (22). In another study, it has been shown that fetal resorptions are increased in mice with shortage of vitamin B6 in their food regimes as compared with the control group (23).

The findings of our study showed that consumption of vitamin B6 before and during pregnancy has positive effects on growth indices but no effect on fetal resorptions of CBZ treated groups. Moreover, we observed eye malformations in CBZ treated groups. Some studies also reported eye malformation due to CBZ consumption during pregnancy (10, 24, 25). Sutcliffe *et al* reported eye malformations such as anophthalmia and

microphthalmia and cloboma in newborns whose mothers consumed CBZ during the first trimester of pregnancy (11). We also did encounter one case report of prenatal CBZ exposure and bilateral anophthalmia. However, other reports did not find any relation between CBZ use during pregnancy and congenital eye malformations (26).

According to our findings, there is an association between CBZ use and eye malformations. Furthermore, we showed that consumption of vitamin B6 before and during pregnancy reduces eye malformations in mice fetuses treated with CBZ. In a study, it has been shown that there is a direct relationship between eye malformations due to CBZ and increased level of homocysteine (27). We may conclude that consumption of CBZ with vitamin B6 reduces the incidence of eye malformations in mice fetuses.

Some clinical and experimental studies have shown that there is a direct relationship between consumption of CBZ and the incidence of NTDs such as spina bifida (8, 16, 18, 28). Many studies reported the role of folic acid in reducing the incidence of NTDs, but little studies were found about the role of vitamin B6 in decreasing NTDs. Candito *et al* in 2006 reported low serum level of vitamin B6 in mothers consuming lamotrigine whose newborns were affected by NTDs (29). In our study, NTDs (in the form of exencephaly) were reduced in experimental groups that were treated with CBZ and vitamin B6. Therefore, we suggest that consumption of vitamin B6 reduces NTDs in mice fetuses and thus it might have a protective role in NTDs.

Some studies indicated that there is a direct relationship between consumption of CBZ and the incidence of orofacial malformations (5, 16, 30-32). Wong study in 1999 reported high serum homocysteine and low concentration of vitamin B6 in mothers with orofacial malformations affected babies (32). Moreover, other studies in mice showed that oral clefting increased in fetuses when food regimes for mice during pregnancy period was without vitamin B6 (23). Furthermore, van Rooij *et al* showed the effect of vitamin B6 in reducing oral clefting (31). Moreover, according to our findings, mandibular hypoplasia incidence was

reduced in experimental groups that received CBZ with vitamin B6, suggesting a role for vitamin B6 in protecting against CBZ-induced facial malformations.

An association between consumption of CBZ and the incidence of limb anomalies in human and animal models have been suggested (33). Furthermore, fingers hypoplasia as a limb malformation has been reported in newborns whose mothers consumed CBZ during pregnancy (16, 18, 34). In our study, limb malformations were significantly reduced in groups treated with CBZ and vitamin B6, once more suggesting a protective role for vitamin B6 against this malformation.

Several reports have shown that using antiepileptic drugs including CBZ in seizure patients reduces serum level of vitamin B6 which leads to hyperhomocysteinemia (13). Moreover, these patients have an abnormal aminothiols redox-status associated with hyperhomocysteinemia (35). One of the teratogenic mechanisms of homocysteine is production of free radicals that leads to oxidative stress (15). On the other hand, suppressive effect of some drugs including CBZ on the speed or volume of myocardial contraction of fetuses can cause ischemia and hypoxia with a resulting production of reactive oxygen species. This mechanism has been suggested as one of the main teratogenic mechanisms of some antiepileptic drugs (36). Vitamin B6 is a member of a group of substances with hydroxyl and amine that binds to pyridine cycle leading to the antioxidant activity of vitamin B6 (12). On the other hand, vitamin B6 promotes the conversion of methionine to glutathione which acts as an antioxidant and has a key role in combating oxidative stress (37).

Conclusion

This study showed that vitamin B6 has a protective effect on the developmental toxicity of CBZ during organogenesis in Balb/c mice.

Acknowledgment

This study is part of a MSc thesis in developmental biology and has been funded by a joint research grant between Mashhad University of Medical Sciences, Mashhad, Iran and Birjand University of Medical Sciences, Birjand, Iran.

References

1. Ornoy A. Neuroteratogens in man: an overview with special emphasis on the teratogenicity of antiepileptic drugs in pregnancy. *Reprod Toxicol* 2006; 22:214-226.
2. Hiremath GK, Kotagal P, Bingaman W, Hovinga C, Wyllie E, Morris H, *et al.*, Risk factors for carbamazepine elevation and toxicity following epilepsy surgery. *Seizure* 2005; 14:312-317.
3. Perez Martin JM, Fernández Freire P, Labrador V, Hazen MJ. Carbamazepine induces mitotic arrest in mammalian Vero cells. *Mutat Res* 2008; 637:124-133.
4. Christensen HD, Rayburn WF, Parker KM, Gonzalez CL, Gold KP. Chronic prenatal exposure to carbamazepine and perinatal outcomes of C3H/He mice. *Am J Obstet Gynecol* 2004; 190:259-263.
5. Matalon S, Schechtman S, Goldzweig G, Ornoy A. The teratogenic effect of carbamazepine: a meta-analysis of 1255 exposures. *Reprod Toxicol* 2002; 16: 9-17.
6. Lindhout D, Hoppener RJ, Meinardi H. Teratogenicity of antiepileptic drug combinations with special emphasis on epoxidation (of carbamazepine). *Epilepsia* 1984; 25:77-83.
7. Tomson T, Battino D. Teratogenic effects of antiepileptic drugs. *Seizure* 2008; 17:166-171.
8. Artama M, Ritvanen A, Gissler M, Isojärvi J, Auvinen A. Congenital structural anomalies in offspring of women with epilepsy--a population-based cohort study in Finland. *Int J Epidemiol* 2006; 35:280-287.
9. Biale Y, Lewenthal H. Effect of folic acid supplementation on congenital malformations due to anticonvulsive drugs. *Eur J Obstet Gynecol Reprod Biol* 1984; 18:211-216.
10. Afshar M, Moallem SA, Houshang Mohammadpour A, Shiravi A, Majid Jalalian S, Jafar Ghalipour M. Teratogenic effects of carbamazepine on embryonic eye development in pregnant mice. *Cutan Ocul Toxicol* 2010; 29:10-15.
11. Sutcliffe AG, Jones RB, Woodruff G. Eye malformations associated with treatment with carbamazepine during pregnancy. *Ophthalmic Genet* 1998; 19:59-62.
12. Kannan K, Jain SK. Effect of vitamin B6 on oxygen radicals, mitochondrial membrane potential, and lipid peroxidation in H2O2-treated U937 monocytes. *Free Radic Biol Med* 2004; 36:423-428.
13. Sener U, Zorlu Y, Karaguzel O, Ozdamar O, Coker I, Topbas M. Effects of common anti-epileptic drug monotherapy on serum levels of homocysteine, vitamin B12, folic acid and vitamin B6. *Seizure* 2006; 15:79-85.
14. Tamura T, Aiso K, Johnston KE, Black L, Faught E. Homocysteine, folate, vitamin B-12 and vitamin B-6 in patients receiving antiepileptic drug monotherapy. *Epilepsy Res* 2000; 40:7-15.
15. Perna AF, Ingrosso D, Lombardi C, Acanfora F, Satta E, Cesare CM, Violetti E, *et al.* Possible mechanisms of homocysteine toxicity. *Kidney Int Suppl* 2003; S137-140.
16. Azarbayjani F, Danielsson BR. Pharmacologically induced embryonic dysrhythmia and episodes of hypoxia followed by reoxygenation: a common teratogenic mechanism for antiepileptic drugs. *Teratology* 1998; 57:117-126.
17. Diav-Citrin O, Shechtman S, Aron J, Ornoy A. Is carbamazepine teratogenic? A prospective controlled study of 210 pregnancies. *Neurology* 2001; 57:321-324.
18. Jones KL, Lacro RV, Johnson KA, Adams J. Pattern of malformations in the children of women treated with carbamazepine during pregnancy. *N Engl J Med* 1989; 320:1661-1666.
19. Vorhees CV, Acuff KD, Weisenburger WP, Minck DR. Teratogenicity of carbamazepine in rats. *Teratology* 1990; 41:311-317.
20. Lumeng L, Cleary RE, Wagner R, Yu P-L, Li T-K. Adequacy of vitamin B6 supplementation during pregnancy: a prospective study. *Am J Clin Nutr* 1976; 29: 1376-1383.
21. Schuster K, Bailey LB, Mahan CS. Vitamin B6 status of low-income adolescent and adult pregnant women and the condition of their infants at birth. *Am J Clin Nutr* 1981; 34:1731-175.
22. Leeda M, Riyazi N, de Vries JJ, Jakobs C, van Geijn HP, Dekker GA. Effects of folic acid and vitamin B6 supplementation on women with hyperhomocysteinemia and a history of preeclampsia or fetal growth restriction. *Am J Obstet Gynecol* 1998; 179: 135-139.
23. Schubert J, Schmidt F, Syska E. B group vitamins and cleft lip and cleft palate. *Int J Oral Maxillofac Surg* 2002; 31:410-413.
24. Piersma AH, Verhoef A, Opperhuizen A, Klaassen R, van Eijkeren J, Olling M. Embryotoxicity of carbamazepine in rat postimplantation embryo culture after in vitro exposure via three different routes. *Reprod Toxicol* 1998; 12:161-168.
25. Williams CP, Marsh CS, Hodgkins PR. Persistent fetal vasculature associated with orbital lymphangioma. *J Aapos* 2006; 10:285-286.
26. Kroes HY, Reefhuis J. Natural history of homocystinuria due to cystathionine beta-synthase deficiency. *Am J Hum Genet* 1985; 37:1-31.
27. Mudd SH, Skovby F, Levy HL, Pettigrew KD, Wilcken B, Pyeritz RE, *et al.* The natural history of homocystinuria due to cystathionine beta-synthase deficiency. *Am J Hum Genet* 1985; 37:1-31.

28. Holmes LB. The teratogenicity of anticonvulsant drugs: a progress report. *J Med Genet* 2002; 39:245-247.
29. Candito M, Gueant JL, Naimi M, Bongain A, Van Obberghen E. Antiepileptic drugs: a case report in a pregnancy with a neural tube defect. *Pediatr Neurol*. 2006; 34:323-324.
30. Wide K, Winbladh B, Kallen B. Major malformations in infants exposed to antiepileptic drugs *in utero*, with emphasis on carbamazepine and valproic acid: a nation-wide, population-based *register* study. *Acta Paediatr* 2004; 93:174-176.
31. Van Rooij IA, Swinkels DW, Blom HJ, Merkus HM, Steegers-Theunissen RP. Vitamin and homocysteine status of mothers and infants and the risk of nonsyndromic orofacial clefts. *Am J Obstet Gynecol* 2003; 189:1155-1160.
32. Wong WY, Eskes TK, Kuijpers-Jagtman AM, Spauwen PH, Steegers EA, Thomas CM, *et al*. *Nonsyndromic orofacial clefts: association with maternal hyperhomocysteinemia*. *Teratology* 1999; 60:253-257.
33. Fritz H, Muller D, Hess R. Comparative study of the teratogenicity of phenobarbitone, diphenylhydantoin and carbamazepine in mice. *Toxicology* 1976; 6:323-330.
34. Ornoy A, Cohen E. Outcome of children born to epileptic mothers treated with carbamazepine during pregnancy. *Arch Dis Child* 1996; 75:517-520.
35. Apeland T, Froyland ES, Kristensen O, Strandjord RE, Mansoor MA. Drug-induced perturbation of the aminothiols redox-status in patients with epilepsy: improvement by B-vitamins. *Epilepsy Res* 2008; 82:1-6.
36. Azarbayjani F, Danielsson BR. Embryonic arrhythmia by inhibition of HERG channels: a common hypoxia-related teratogenic mechanism for antiepileptic drugs? *Epilepsia* 2002; 43:457-468.
37. Hamelet J, Seltzer V, Petit E, Noll C, Andreau K, Delabar JM, *et al*. Cystathionine beta synthase deficiency induces catalase-mediated hydrogen peroxide detoxification in mice liver. *Biochim Biophys Acta* 2008; 1782:482-488.